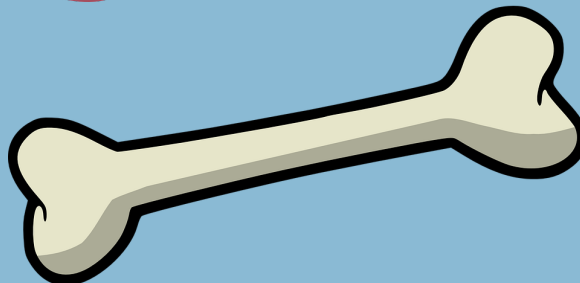




Management of Pediatric Supracondylar Humerus Fractures


Must be evaluated by an orthopedic surgeon



Have suspicion for concomitant nerve and vascular injuries, ipsilateral distal radius fractures



If vascular compromise immediate closed reduction indicated



ACS TQIP
BEST PRACTICES IN
THE MANAGEMENT
OF ORTHOPAEDIC
TRAUMA



ACS
tqip
TRAUMA
QUALITY
IMPROVEMENT
PROGRAM